

From: Juline Stratton-Kerr supachic@att.net  
Subject: 2 & 3 of 3 | Fwd: Juline Kerr - Patient Records and X-rays from  
Dr Rhea  
Date: Apr 27, 2022 at 11:17:00 AM  
To: images@drbillstewart.com

Hello Dr. Stewart,

To follow is Dr. Metz documentation and after that is Dr. Rhea from Houston Texas in regards to the implant as well as patient records for my appointment scheduled on May 4, 2022 at 4 PM

11:15

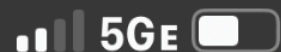

< Search



○ Dr. Paul Metz | oral maxillofacial  
surgeons of Houston

7:21



Done

20090921 impph1.doc



Monday, September 21, 2009

Ron Rhea D. D. S.  
701 Town & Country Blvd. #222  
Houston, TX 77024

Re: Julie Kerr

Dear Ron,

We appreciate the opportunity to work with you in the restoration of Julie Kerr. Surgical placement of one single root form endosseous implant for site # 3 with a 3mm healing abutment was accomplished uneventfully on Friday, September 18, 2009. Julie will be seen post-operatively on Wednesday, September 30, 2009 . We

will see her again in approximately three months to check on the osseointegration process.

We have enclosed a duplicate of the postoperative x-ray. A diagram of the implant placed with appropriate sizes is indicated below. In this case, the brand used was NOBEL BIO CARE REPLACE SELECT.

MAXILLA  
5.0  
X10  
R-----  
-----L  
MANDIBLE

Please do not hesitate to call our office if you have any questions or concerns regarding the case or treatment rendered in our office. Again, we appreciate this opportunity to assist you in providing professional care to our patient.

Sincerely,

Paul S. Metz, D.D.S., M.D.

Patti Wallis  
Oral & Maxillofacial Surgeons of Houston

Notice: The information contained in this e-mail communication is privileged and confidential information intended only for the use of the individual it was addressed. If the reader of this message is not the intended recipient, you are hereby notified that any dissemination, distribution or copy of this communication is strictly prohibited. If you have received this in error, please contact the sender and delete the material from any computer.

11:15



7:21 ↵

5G E 

[Done](#)

20100310 ImpPh2prevhc.doc



Wednesday, March 10, 2010

Ron Rhea D. D. S.  
791 Town & Country Blvd. #222  
Houston, TX 77024

Dear Ron,

Mrs Julie Kerr was seen in our office for a Phase II implant evaluation on Tuesday, March 09, 2010. If you recall, a healing abutment was placed at the time of implant insertion. The implant looks good and Julie is ready to be scheduled in your office for implant reconstruction.

Please feel free to call our office with any questions regarding the prosthetic/reconstruction procedures. We would appreciate your saving the healing abutments for us in the enclosed envelope. When you have accumulated 10 caps let us know and we will retrieve them and bring lunch for your staff. The implant diameter for site # 3 is Nobel Biocare Replace Select 5.0.

Please advise us of the completion of the restoration. We would like to see this patient periodically to monitor the care and status of the implant.

Sincerely,

Paul Metz, D.D.S., M.D.

Patti Wallis  
Oral & Maxillofacial Surgeons of Houston

---

Notice: The information contained in this e-mail communication is privileged and confidential information intended only for the use of the individual it was addressed. If the reader of this message is not the intended recipient, you are hereby notified that any dissemination, distribution or copy of this communication is strictly prohibited. If you have received this in error, please contact the sender and delete the material from any computer.

Best regards  
Juline A. Kerr  
Ph: (808)866-4566  
Em: supachic@att.net  
Sent from my iPhone 13 PRO Max

Begin forwarded message:

**From:** The Dentists at Town & Country Village <[office@dentistsattcv.com](mailto:office@dentistsattcv.com)>  
**Date:** February 8, 2022 at 2:23:01 PM EST  
**To:** "Juline A. Kerr" <[jkerr18@jh.edu](mailto:jkerr18@jh.edu)>  
**Subject:** Juline Kerr - Patient Records and X-rays from Dr Rhea

External Email - Use Caution

Hi Juline. Attached are you patient chart records along with x-rays. There are 7 bitewing x-rays (3/3/16), #2 single x-ray (3/3/16), #19 single x-ray (3/3/16) and one right side bitewing x-ray (8/16/16) attached.

Thank you,

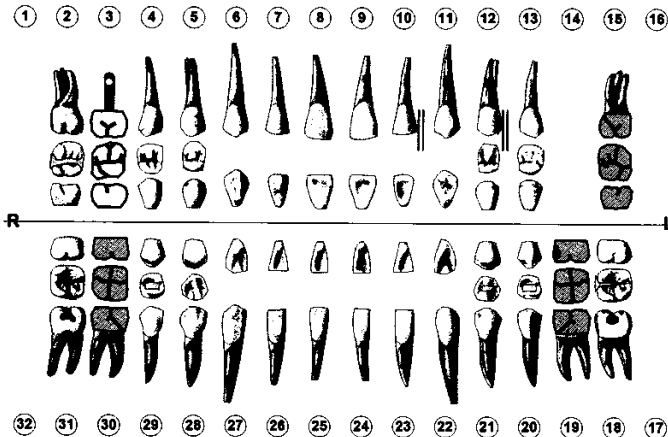
Patty (for Dr Rhea)

**The Dentists at Town & Country Village**  
(713) 467-3458  
791 Town and Country Blvd, Suite 222, Houston, Texas 77024  
[www.dentistsattcv.com](http://www.dentistsattcv.com)

## Patient Progress Notes

Patient: **Julline Kerr**  
 Provider: **Ronald L. Rhea, DDS**  
 Phone: **(713)467-3458**  
 Office: **791 Town & Country Blvd, #222**  
**Houston, TX 77024-3925**

Date: **2/8/2022**  
 Birthdate: **5/6/1978**



☒ Treatment Plan
 ☒ Completed
 ☒ Conditions
 ☒ Existing-This Prov
 ☒ Existing-Other Prov

Date	Tooth	Surface	Proc	Prov	Description	Stat
12/8/2009				D1RR	Perio Exam	
12/8/2009			D0150	D1KO	Comprehensive oral evaluation	C
12/8/2009			D0273	D1KO	Bitewing Three Image	C
12/8/2009			D0274	D1KO	Bitewing Four Image	C
12/8/2009			D0330	D1KO	Panoramic Image	C
12/8/2009			D4355	D1KO	Full mouth debridemnt,eval/diag	C
12/8/2009	1		15100	D1RR	Missing tooth, more than a year	CON
12/8/2009	2	MOD	D2393	D1RR	Resin composite-3s, posterior	EO
12/8/2009	3		15100	D1RR	Missing tooth, more than a year	CON
12/8/2009	3		D6010	D1RR	Surg place implant: endosteal	EO
12/8/2009	14		D2750	D1RR	Crown-porc fuse high noble mtl	EO
12/8/2009	14		D3330	D1RR	Endo therapy - molar (ex rest)	EO
12/8/2009	15		D2750	D1RR	Crown-porc fuse high noble mtl	EO
12/8/2009	16		15100	D1RR	Missing tooth, more than a year	CON
12/8/2009	17		15100	D1RR	Missing tooth, more than a year	CON
12/8/2009	18	B	D2140	D1RR	Amalgam-1 surf. prim/perm	EO
12/8/2009	18	MO	D2392	D1RR	Resin composite-2s, posterior	EO
12/8/2009	19		D2750	D1RR	Crown-porc fuse high noble mtl	EO
12/8/2009	19		D3330	D1RR	Endo therapy - molar (ex rest)	EO
12/8/2009	20	O	D2391	D1RR	Resin composite-1s, posterior	EO
12/8/2009	21	O	D2391	D1RR	Resin composite-1s, posterior	EO
12/8/2009	29	O	D2391	D1RR	Resin composite-1s, posterior	EO
12/8/2009	30		D2750	D1RR	Crown-porc fuse high noble mtl	EO
12/8/2009	31	OB	D2150	D1RR	Amalgam-2 surf. prim/perm	EO
12/8/2009	32		15100	D1RR	Missing tooth, more than a year	CON
12/15/2009			CORSP	D1RR	Correspondence from specialist	C

## Patient Progress Notes

Patient: **Juline Kerr**  
Provider: **Ronald L. Rhea, DDS**  
Phone: **(713)467-3458**  
Office: **791 Town & Country Blvd, #222**  
**Houston, TX 77024-3925**

Date: **2/8/2022**  
Birthdate: **5/6/1978**

Date	Tooth	Surface	Proc	Prov	Description	Stat
------	-------	---------	------	------	-------------	------

Mrs Julie Kerr was seen for consultation and evaluation for possible Implant/Prosthetic surgery on Thursday, August 27, 2009. Her husband Shannon is a patient of yours and he has encouraged her to see you.

I feel her preliminary diagnosis is:

Edentulous dental site #3

For which the following treatment plan is submitted. Please consider:

Surgical placement of a single root form implant to site for single crown reconstruction.

Julie is scheduled for surgery September 18, 2009

Once again, I look forward to working with you in the oral rehabilitation of our patient.

Paul S. Metz, D.D.S., M.D.

6/23/2010 CORSP D1RR Correspondence from specialist

C

## Patient Progress Notes

Patient: **Juline Kerr**  
Provider: **Ronald L. Rhea, DDS**  
Phone: **(713)467-3458**  
Office: **791 Town & Country Blvd, #222**  
**Houston, TX 77024--3925**

Date: **2/8/2022**  
Birthdate: **5/6/1978**

Date	Tooth	Surface	Proc	Prov	Description	Stat
------	-------	---------	------	------	-------------	------

Dear Ron,

Mrs Julie Kerr was seen in our office for a Phase II implant evaluation on Tuesday, March 09, 2010. If you recall, a healing abutment was placed at the time of implant insertion. The implant looks good and Julie is ready to be scheduled in your office for implant reconstruction.

Please feel free to call our office with any questions regarding the prosthetic/reconstruction procedures. We would appreciate your saving the healing abutments for us in the enclosed envelope. When you have accumulated 10 caps let us know and we will retrieve them and bring lunch for your staff. The implant diameter for site # 3 is Nobel Biocare Replace Select 5.0.

Please advise us of the completion of the restoration. We would like to see this patient periodically to monitor the care and status of the implant.

Sincerely,

Paul Metz, D.D.S., M.D

## Patient Progress Notes

Patient: Julie Kerr  
Provider: Ronald L. Rhea, DDS  
Phone: (713)467-3458  
Office: 791 Town & Country Blvd, #222  
Houston, TX 77024-3925

Date: 2/8/2022  
Birthdate: 5/6/1978

Date	Tooth	Surface	Proc	Prov	Description	Stat
------	-------	---------	------	------	-------------	------

Wednesday, March 10, 2010

Ron Rhea D. D. S.

791 Town & Country Blvd. #222

Houston, TX 77024

Dear Ron,

Mrs Julie Kerr was seen in our office for a Phase II implant evaluation on Tuesday, March 09, 2010. If you recall, a healing abutment was placed at the time of implant insertion. The implant looks good and Julie is ready to be scheduled in your office for implant reconstruction.

Please feel free to call our office with any questions regarding the prosthetic/reconstruction procedures. We would appreciate your saving the healing abutments for us in the enclosed envelope. When you have accumulated 10 caps let us know and we will retrieve them and bring lunch for your staff. The implant diameter for site # 3 is Nobel Biocare Replace Select 5.0.

Please advise us of the completion of the restoration. We would like to see this patient periodically to monitor the care and status of the implant.

Sincerely,

Paul Metz, D.D.S., M.D.

ReplyReply AllMove...InboxArrayDeleted Deleted ItemsMemoriesPersonalReadReceipts, Confirmati...Sent ItemsTDAUTDB Flag this messageDr. Meta pt. Julie KerrFriday, March 12, 2010 9:23 AMFrom: "Patti Wallis" <patti@omsh.us>Add sender to ContactsTo: rhea@tda.org

## Patient Progress Notes

Patient: Julie Kerr  
 Provider: Ronald L. Rhea, DDS  
 Phone: (713)467-3458  
 Office: 791 Town & Country Blvd, #222  
 Houston, TX 77024-3925

Date: 2/8/2022  
 Birthdate: 5/6/1978

Date	Tooth	Surface	Proc	Prov	Description	Stat
------	-------	---------	------	------	-------------	------

Wednesday, March 10, 2010

Dear Ron,

Mrs Julie Kerr was seen in our office for a Phase II implant evaluation on Tuesday, March 09, 2010. If you recall, a healing abutment was placed at the time of implant insertion. The implant looks good and Julie is ready to be scheduled in your office for implant reconstruction.

Please feel free to call our office with any questions regarding the prosthetic/reconstruction procedures. We would appreciate your saving the healing abutments for us in the enclosed envelope. When you have accumulated 10 caps let us know and we will retrieve them and bring lunch for your staff. The implant diameter for site # 3 is Nobel Biocare Replace Select 5.0.

Please advise us of the completion of the restoration. We would like to see this patient periodically to monitor the care and status of the implant.

Sincerely,

Paul Metz, D.D.S., M.D.

6/23/2010	3	D6065	D1RR	Implant supp porc/cer crown	C
Dr Metz placed Nobel Biocare Replace Select 5.0mm x 10mm Implant...ph					
7/13/2010	3	D2700	D1RR	SEAT CROWN	C
8/31/2010		NOTE	D1RR	Patient information note	EO
	shade A1				
5/19/2011		NOTE	D1RR	Patient information note	E
Pt getting settlement soon and wants to do full trmt along with bleaching. Sch'd for px to address any other trmt needed 5/24/11.....ph					
3/3/2016			D1RR	Perio Exam	
3/3/2016		D0150	D1RR	Comprehensive oral evaluation	C

## Patient Progress Notes

**Patient:** Juline Kerr  
**Provider:** Ronald L. Rhea, DDS  
**Phone:** (713)467-3458  
**Office:** 791 Town & Country Blvd, #222  
 Houston, TX 77024-3925

**Date:** 2/8/2022  
**Birthdate:** 5/6/1978

Date	Tooth	Surface	Proc	Prov	Description	Stat
CC: tooth ache UR. #2 sens to cold per pt. #2 sens to percussion as are bicusps in quadrant. RR suspect bruxism. PA neg. Tooth has very large fill and needs a crn. Discuss full treatment plan. Pt says her bite is off since loss of #14, and she is biting lip a lot. Contact open D #10 and 12. (Pt asked about ortho after RR had finished exam). Ref to OMSH for implant. OH is good. Pt is using sonicare. Tissue extremely tender to probing so pocket depth may be deeper than recorded. Pt will need anesthesia to remove sub G calc noted on bw and new probing w/ local. Xerostomia also noted. Discuss pt's increased risk of caries. ST-wNL RR, bo						
3/3/2016			D0273	D1BP	Bitewing Three Image	C
3/3/2016			D0274	D1BP	Bitewing Four Image	C
3/3/2016			D0330	D1BP	Panoramic Image	C
3/3/2016			EMAIL	D1RR	Email	E
to: reception@omsh.us: Sent panorex to Dr Metz for #14 implant. AK						
3/3/2016			HH	D1RR	Health History Update	C
Deep vein thrombosis - 2013 -RX: seroquel 800 mg, Vyvanse 70mg, Implanted morphine pump, premarin 1.25 mg, baclofen 20 mg, Allergy :Asprin-hives, b						
3/3/2016	10		15113	D1RR	Open contact - Distal	CON
3/3/2016	12	D	15105	D1RR	Caries/decay	CON
3/3/2016	12		15113	D1RR	Open contact - Distal	CON
3/3/2016	14		D7140	D1RR	Extract,erupted th/exposed rt	EO
3/3/2016	19	ML	15107	D1RR	Recurring caries/surface restor	CON
4/4/2016			D9230	D1RR	Analgesia-inhal of nitrous oxid	C
115/ 60 P 111,: 9:02 am O2 started w/ 6 lpm. 9:13 N2O started by RR at 4.5 lpm. 9:56 O2 flush. Patient tolerated procedure well, alert, oriented, and ambulatory at dismissal b						
4/4/2016	LL		D4341	D1BP	Perlo scale/root pln-4+per quad	C
1 carp septicocaine. SRP LLQ. Tissue very puffy iprox 18-19. 6mm DL #19. Scalew w/ Piezo R/L straight and curette and scale w/ hand curettes. Mod iprox bleeding. Instr DFing sub G and soft pick. Pt wishes 2 quads next appt. Pt tolerated procedure well. Discuss study model to eval bite and shifting UL. Enc pt to have crns done LL. Pt told of recurrent decay #9. Margins are bulky or overhand on DB. May be contributory to puffiness here. Pt OH is very good w/ TB. b						
7/11/2016	3		D6065	D1RR	Implant supp porc/cer crown	C
Pt fx tooth over implant while eating hard candy. Six year old crown. Reimpressed implant abutment directly. Shade 1.5 M2. RLR/ss						
8/16/2016	3		D6000	D1RR	Seat implant Crown	C
Seat with Rely-X Luting cement. Adj bite and polish. RR/bc						
5/18/2017			D9986	D1EM	Missed appointment	C
No Show Confirmed appt...bam						
5/22/2017			EMAIL	D1RR	Email	E
to pt: Hi Juline, see attached treatment plan for the work we discussed for a total fee of \$6942. Please call your insurance company and get your reimbursement amount for the circled treatment codes only and give them our fee for service. You can go online to www.carecredit.com and apply for a health credit card and ask for a \$7000 credit limit to cover this plan. Please call as soon as you can to schedule as we are limited in time before you leave for Maui.						
Thankyou, Patty (t/p: crowns #'s 2, 31, 38, 19; filing #12 and 3 quads srp w/nitrous)...ph						
5/22/2017			NOTE	D1RR	Patient information note	E
Called pt to see if she had rec'd t/p thru e-mail and she said she had Salmonella infection and had not checked it. Also then informed me that she was on blood thinner medication and would have to be off 10 days for any trmt. (Could have informed us early this morning when she wanted to be seen). So suggested she have her trmt done in Maui when she moves on June 6th due to insufficient time to give her any services before she leaves. ....ph						
2/7/2022			PHONE	DRRR	Telephone Cons w/ patient	C
Pt called to request her x-rays and records to be e-mailed to her. Pt gave us a new e-mail address to use (jkem18@jh.edu). Sent her an e-mail that we would need her to request them via e-mail for our records. (ph)						
2/8/2022			EMAIL	DRRR	Email	C
Pt sent e-mail requesting her records be sent to her return e-mail. (see doc ctr). ph						

## Patient Progress Notes

Patient: **Juline Kerr**  
Provider: **Ronald L. Rhea, DDS**  
Phone: **(713)467-3458**  
Office: **791 Town & Country Blvd, #222**  
**Houston, TX 77024-3925**

Date: **2/8/2022**  
Birthdate: **5/6/1978**

Date	Tooth	Surface	Proc	Prov	Description	Stat

UL=Upper Left UR=Upper Right LL=Lower Left LR=Lower Right

Page: 7 of 7

